

An Audit of Vascular Surgery Experience at North Surgical Unit, Mayo Hospital Lahore

K IRSHAD O SALAHUDDIN I U RASHID S RAZA A M CHAUDHRY

Department of Surgery King Edward Medical University/Mayo Hospital Lahore

Correspondence: KhalidIrshad@doctors.org.uk

The prevalence of Peripheral vascular disease, Carotid artery stenosis and Aortic aneurysm in our society is higher than generally accepted because of higher incidence of established modifiable risk factors like Smoking, Diabetes, Hypertension and Hyperlipidaemia. We present a review of 246 patients with prospective collection of data who were referred for opinion to North Surgical Ward Mayo Hospital Lahore from March 2005 to February 2006. Surgical treatment was possible in 165 patients. Amongst remaining 81 patients 38 presented late and had amputations either in referring unit or with us and 43 were managed conservatively or under follow up. 24 prosthetic grafts were used, 8 in Aortic aneurysms, 4 in carotid endarterectomies and 11 in iliofemoral reconstructions with no peri-operative mortality or stroke. We had 2 grafts occlusion and amputations in critically ischaemic patients who had single vessel run off. Non invasive investigations were the first choice in Carotid and peripheral vascular disease.

Conclusion: Our experience shows higher incidence of late presentation and under treatment of these high risk patients which need patient awareness and life style modification at community level. We advocate multidisciplinary approach and establishment of fully supported dedicated peripheral vascular and endovascular services at tertiary care level.

Key words: Surgical audit, vascular

Mayo hospital is a tertiary referral center for major complicated general surgical and vascular emergencies resulting from gunshot, stab wounds and road traffic accident. We also receive fair number of elective referrals. Aim of this review was to determine risk factors, evaluate our existing practices with no existing protocols and audit the outcome of surgical procedures to improve quality of care. We reviewed the outcome in patients who were referred to or presented with the signs and symptoms of vascular disease.

Patients and methods:

All patients referred with signs and symptoms of vascular diseases from March 2005 to February 2006 were included in this review. Data was prospectively collected on a standard printed questionnaire. Information obtained were patient demographics, mode of admission, clinical condition on admission, associated comorbidity, investigations, diagnosis, surgical treatment offered, complications and follow up.

Results:

A total of 246 patients were referred during the study period for opinion. 182 were male and 64 were female.

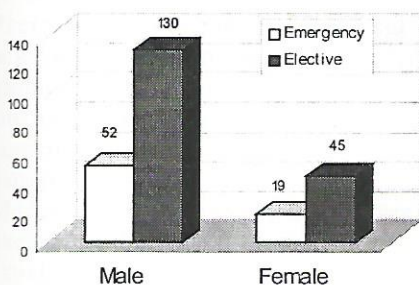


Fig 1: Sex distribution

175 patients were referred electively for opinion.

We received elective referrals through outpatient department, from other teaching surgical units/hospitals in the town, Physicians, Cardiologist and Cardiac surgery colleagues. We also received direct referral from Radiology department regarding incidental vascular findings in patients coming for routine investigations. 165 patients received surgical treatment (Fig2).

Type of cases

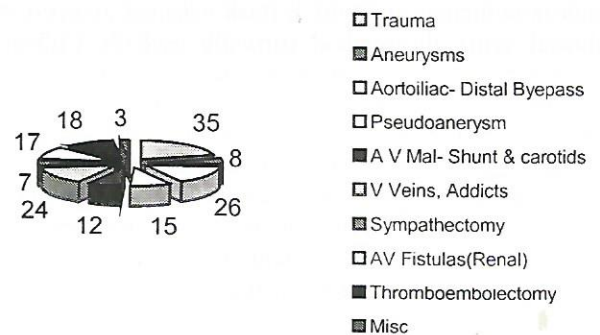
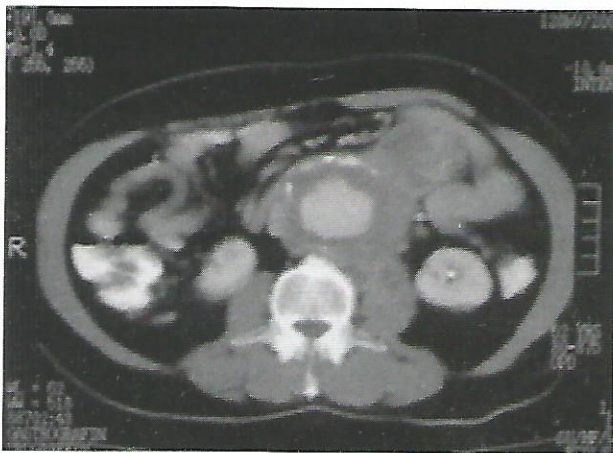


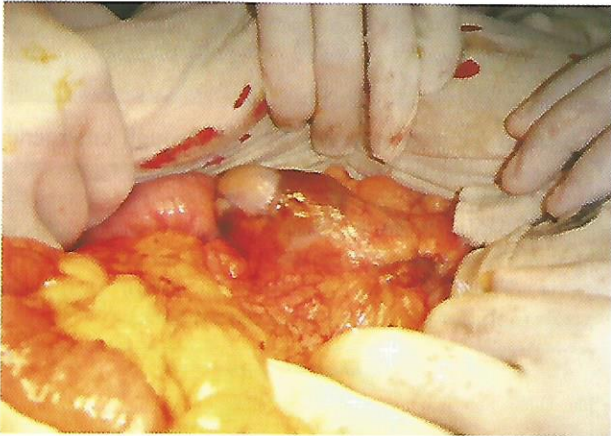
Fig 2

Amongst elective group we treated patients for aneurysmal disease, peripheral vascular disease presenting with intermittent claudication or ischemic rest pain and Carotid artery stenotic disease presenting with recurrent Transient Ischemic attacks and also patients with venous pathology. 17 patients were referred for treatment of abdominal aortic aneurysm(AAA). Nine patients were managed on intention to treat basis. 8 patients had aortic replacement graft(Fig3-4) including 1 patient with leaking aneurysm and 1 with suprarenal AAA. He had tube graft through thoracoabdominal approach. Graft was beveled anteriorly to save superior mesenteric and right renal

artery and left renal artery reimplanted. One patient who presented with severe abdominal pain and hypotension, procedure was abandoned due to abdominal aortic aneurysm extending upto celiac axis. 2 patients who have aneurysm of 5.5 cm size are on waiting list for surgery. One patient presented with leaking abdominal aortic aneurysm in A&E. He was morbidly obese high risk patient who had history Myocardial Infarction 6 weeks ago. He was kept comfortable and died in peace 4 hours after the admission. Remaining four patients in aneurysm group have small aneurysms measuring 4.2-4.5cm diameter on ultrasound. They are under 6 monthly follow up regime. We had no 30 day mortality in surgically treated aneurysm patients.

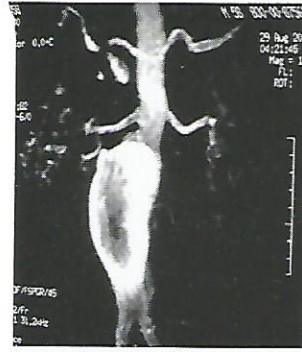

3a.

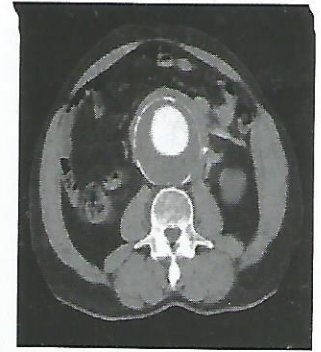


3b.

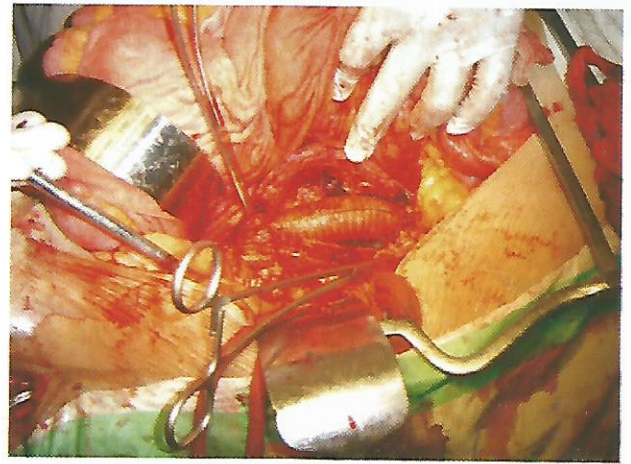Fig 3
CT Scan(a) and operative picture(b) of a patient with contained leak from Abdominal Aortic aneurysm



4a.



4b.



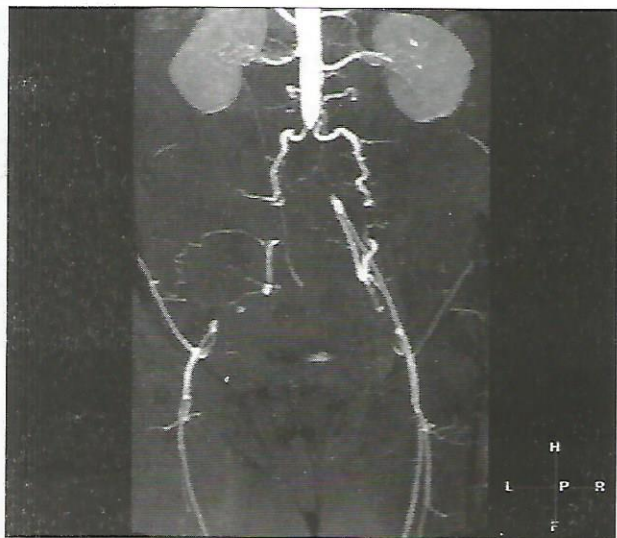
4c.

Fig: 4: MR Angio(a), CT Angio(b) of a patient with inflammatory Abdominal Aortic Aneurysm who had 20 mm tube graft(c).

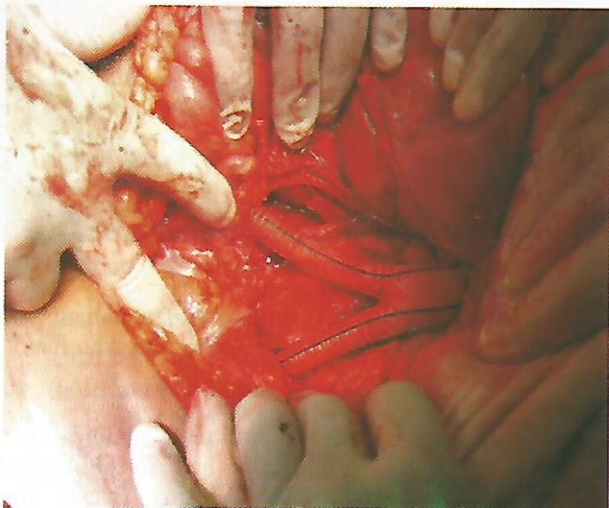Patients presenting with intermittent claudication , ischemic rest pain and ulceration had Aortobifemoral, IleoFemoral and Femoropopliteal grafts. Twenty four patients received prosthetic grafts (Tab 1). We had two graft failure in elective group. One patient had ileofemoral and other one had femorodistal popliteal prosthetic graft.

Table 1: Prosthetic grafts

| Prosthetic grafts | No. |
|---|-----|
| Aortic Tube Graft (HEMASHIELD, GORE-TEX [®]) | 4 |
| Aortic Bifurcate Graft (HEMASHIELD, GORE-TEX [®]) | 6 |
| IleoFemoral/ Femoropopliteal (VASCUTEK TERUMO) | 8 |
| Carotid Patch (VASCUTEK TERUMO) | 4 |
| Axillo-Brachial Bypass (MAXIFLO-VASCUTEK TERUMO) | 1 |
| Brachio-Cephalic Fistula Renal Access (GELSOFT VASCUTEK TERUMO) | 1 |



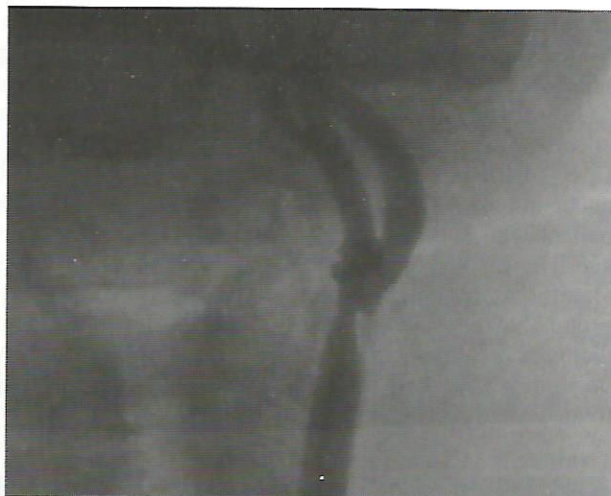5a.



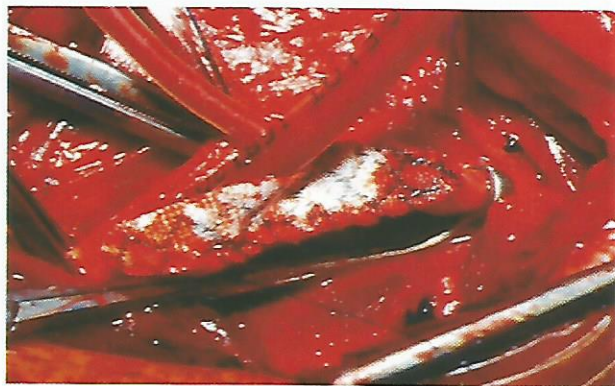
5b.

Fig 5: MR Angio(a) and Aortobifemoral graft(b) in a critically ischaemic patient with Bilateral Iliac Disease

Carotid Artery disease patients presented with recurrent TIAs. We routinely use Javid Shunt and prosthetic patch (fig 6). Other group of patients who received elective treatment were, patients with Varicose Veins 15, Arterio-venous malformations, Portal vein thrombosis in 2, one had proximal splenorenal shunt for massive recurrent GI bleed and hypersplenism. The other one waiting for surgery, Cervical rib resection in 1 patient who had neurovascular compression, lumbar sympathectomy in 7 patients who had advanced peripheral vascular disease not amenable for vascular reconstruction and AV fistulas in 17 patients for dialysis.



6a.



6b.

Fig 6: Arch Angiogram (a) and left Carotid Endarterectomy(b) and patch in a patient who had combined procedure prior to CABG

A total of 71 patients were treated through emergency (Fig 7) for vascular injuries including isolated vascular injuries and also associated intra-abdominal visceral injuries resulting from gunshot, stab wounds and road traffic accidents.. Fifty two were male and nineteen were female. These injuries involved all major peripheral vessels including 2 inferior vena cava injuries.

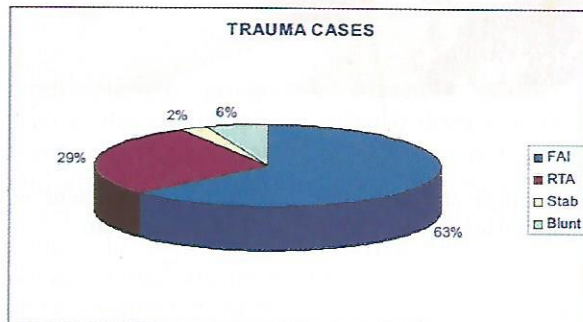


Fig. 7

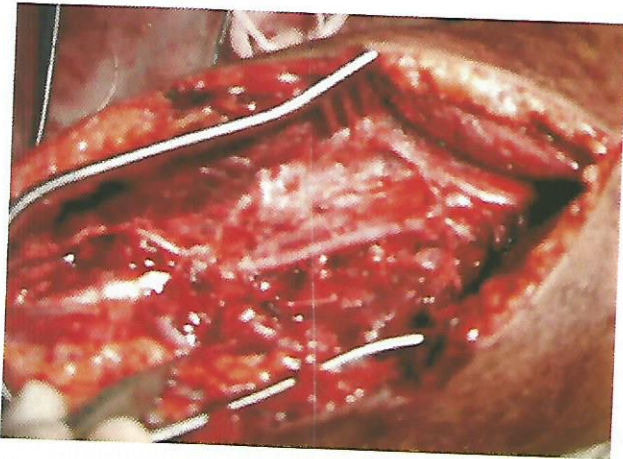
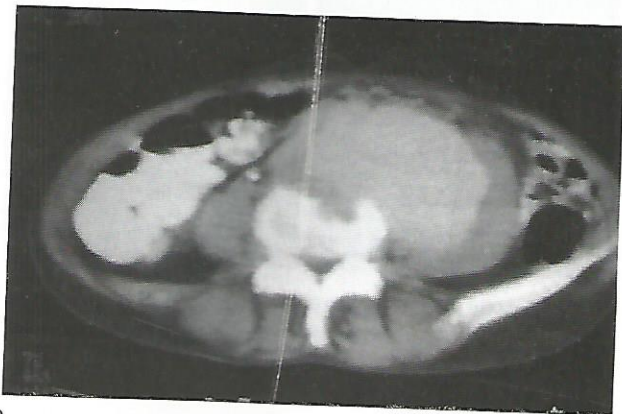
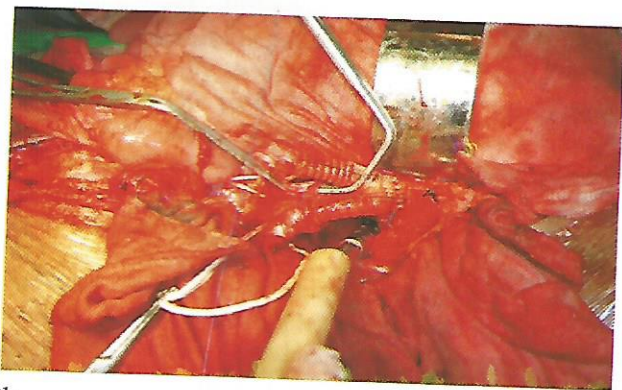


Fig 8: Reverse Saphenous graft in a patient who sustained gunshot injury to his femoral artery.

We also received late complications of vascular trauma as aortic (Fig 9), carotid, subclavian, axillary, brachial, radial, femoral and popliteal pseudoaneurysm.

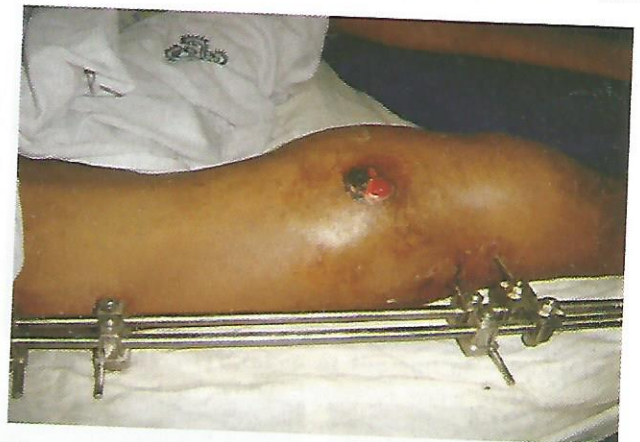

9a.

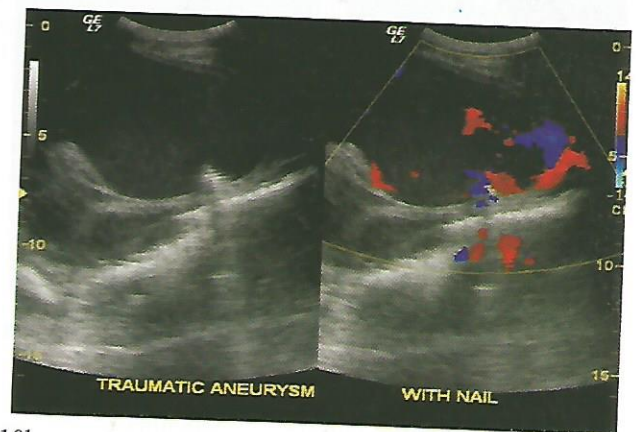


9b.

Fig 9: CT angio of a patient who had nearly 12cm pseudoaneurysm following iatrogenic injury to Aortoiliac bifurcation during spinal fixation for caries spine.



10a.



10b.

Fig:10: Pseudoaneurysm of Popliteal Artery following Traumatic injury with External fixator pin, nicely displaced by Colour Doppler

Future:

In last few years Vascular surgery has changed on extremely rapid pace and there has been trend towards less invasive treatment modalities ie endovascular procedures. Endovascular procedures utilize a minimally invasive technology to treat patients arterial disease (aneurysmal and occlusive) from inside the artery. These endovascular procedures avoid major vascular surgery and are safer and better than open repair when applied properly. Mortality rate of endovascular procedures is substantially less than that of open vascular surgery. Aortic (Fig 11), Peripheral endovascular and carotid Angioplasty/ stenting(Fig12)facility is not available in any teaching hospital in Punjab. Although cost is the main limiting factor we are hoping to establish these facilities available in Mayo / King Edward Medical University Hospital Lahore in near future.

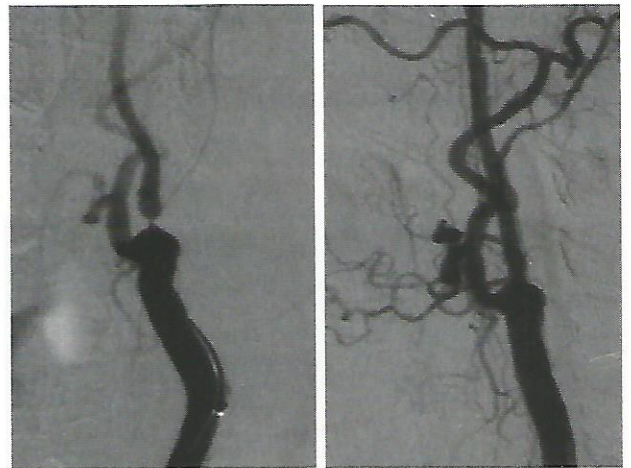
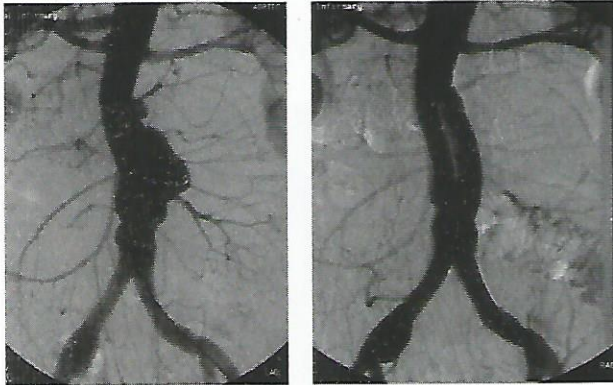




Fig 11 :Endovascular repair (EVAR) in a patient who was unfit for open repair because of coexisting co-morbidities.

Acknowledgement:

We are thankful to Mr Donald B Reid, Consultant Vascular & Endovascular Surgeon for his continued support providing us prosthetic grafts.

Fig 12: Carotid stenting in a patient with high grade stenosis of internal carotid artery