

## Research Article

# Maternal Hypothyroidism Influences the Weight of Brain and Impairs the Migration of Neurons Inside the Hippocampus of Neonatal Rat

Mariyah Hidayat,<sup>1</sup> Khayyam Arif Rana,<sup>2</sup> Nabila Kaukab<sup>3</sup>

<sup>1-3</sup>University College of Medicine and Dentistry, University of Lahore

### Abstract

**Objective:** To histologically observe the effects of hypothyroidism on the hippocampus of neonatal rats.

**Methods:** A total of 10 healthy female Wistar rats, between 12-16 weeks old, were randomly divided into 2 groups; Group A was labelled as control and Group B was made hypothyroid by giving 15mg/kg of Propylthiouracyl (PTU) daily mixed in chow. The treatment was continued for a week before they were allowed to mate and conceive, and it was not interrupted throughout pregnancy and delivery until 21st day of lactation. On the 22nd day, 10 pups from each of the two groups were euthanized; 3cc of blood was drawn out from the heart immediately and the brains were scooped out, weighed, fixed in formalin after slicing out the cerebrum along with hippocampus, processed and stained to observe the arrangement and count and number of pyramidal neurons of CA3 region of hippocampus.

**Results:** There was a significant decrease in the brain weights of group B pups ( $1.21 \pm 0.21$ mg) when compared to the control group A ( $1.42 \pm 0.01$ mg). The thyroxine (T4) level from the experimental group B was significantly decreased ( $27.7 \pm 1.2$  ng/dl) compared to control ( $32.1 \pm 0.9$  ng/dl). Moreover, the serum levels of TSH were significantly higher in group B ( $21 \pm 3.7$ ng/dl) as compared to group A ( $15 \pm 2.4$  ng/dl). The number of pyramidal cell count in group B was significantly decreased ( $39 \pm 1.24$  per unit area) as compared to group A ( $44 \pm 2.49$  per unit area).

**Conclusion:** Maternal hypothyroidism not only exerts its' influence on the arrangement of Pyramidal neurons of CA3 area of hippocampus, but it also decreases their count. Overall, it effects the weight of the brain and significantly raises the levels of TSH in the neonates.

**Corresponding Author** | Prof. Mariyah Hidayat, Professor of Anatomy, University College of Medicine and Dentistry, University of Lahore **Email:** mariyah.hidayat@ucm.uol.edu.pk

**Keywords** | Hypothyroidism, Hippocampus, CA3 region, Pyramidal neurons, Propylthiouracil.

### Introduction:

In larger mammals, cerebrum constitutes a major portion of the brain, which comprises of the cerebral cortex and many subcortical structures, including the hippocampus. The hippocampus, by evolution, is one of the oldest parts of the brain, residing in the temporal lobe and forming an integral component of the limbic system.<sup>1</sup> It regulates functions of the body, including motivation, emotion, learning, and memory.<sup>2</sup> There are

increasing number of Thyroid Hormone (TH) receptors in developing neurons of fetal brain and their count is affected in both hypo- and hyper-thyroid states, leading to irreversible morphological changes, if not treated immediately after birth.<sup>3</sup> Thyroid hormones influence the proliferation, apoptosis, migration, and differentiation of many neuronal and glial cell types during the development of brain in rat species during the first three weeks of life.<sup>4</sup> TH receptors are present in the hippocampal neurons which are extremely sensitive to the

changes in TH level during first postnatal month in both rodents and humans.<sup>5</sup> During each stage of neuronal development, reduction or absence of THs leads to alterations in molecular organization, morphology and functions in the motor neurons of hippocampus.<sup>6</sup>

Anatomically, the hippocampus is comprised of 2 main components - the dentate gyrus and Cornu Ammonis (CA), which in turn, is distinguished structurally and functionally into 4 distinct subfields named CA1, CA2, CA3 and CA4.<sup>7</sup> The CA3 area has been the major focus of researchers in the past few years because of the major role it plays in memory processes. Neuronal connection in the CA3 area is denser than that of other areas.<sup>8</sup> The neonatal rat is the ideal and most frequently used animal model of brain development to study the effects of deficient TH levels on this organ.<sup>9</sup> Although the volume of the hippocampus is 100 times larger in man than in rat, the basic hippocampal architecture is similar to both species.<sup>10</sup>

A gap in knowledge has been identified pertaining to the effect of low thyroid hormone levels on functions of pyramidal neurons of hippocampus. It has been observed that hypothyroidism causes degeneration of neurons<sup>5</sup>, but its direct effects on the arrangement of pyramidal neurons in CA3 area of hippocampus during intrauterine life and in early neonatal period has not been documented. This experiment on 22 days old pups has observed the effects of low maternal and neonatal serum levels of thyroid hormones on the arrangement of pyramidal neurons of hippocampus.

### Methods:

After having approved the research proposal by the Ethical Review Committee of University of Health Sciences (UHS), Lahore, this experiment was commenced, strictly following the protocol and guidelines laid down by American Veterinary Medical Association (AVMA) for sacrificing animals.<sup>11</sup>

The total duration of this experiment was from January - March 2019, around 8 to 9 weeks, including all the experimental work. Ten healthy female Wistar rats, 12-16 weeks old, falling in the weight range of 180 -220 grams, were equally divided into 2 groups by simple randomization, with 5 rats in each group and acclimatized in their allotted cages a week before starting the experiment. Group A was labelled as control. Group B was made hypothyroid by giving 15mg/kg of propyl-

thiouracyl (PTU) daily mixed in chow. Propylthiouracyl with the trade name of Procarbazole (50mg tablets) were purchased from a local pharmacy and grinded thoroughly. After carefully weighing the medicine, the pellets were prepared from powder form of PTU and mixed in rat chow daily. Group A was labelled as control and Group B was made hypothyroid by giving 15mg/kg of Propylthiouracyl (PTU) daily mixed in chow. The treatment was continued for a week before they were allowed to mate and conceive. The appearance of the vaginal plug was labelled as the first day of pregnancy. Propylthiouracyl was given to the mothers throughout pregnancy and lactation, but the effects of this drug were observed on the hippocampus of their 22 days old pups, 10 from each group. Mothers continued to take PTU throughout the period of pregnancy and lactation. The total number of pups born from the control group was 29 whereas from the hypothyroid mothers, the total number of pups was only 19, out of which 5 died immediately after birth.

Maternal serum levels of T3, T4 and TSH were measured twice during the study i.e during the first week of pregnancy and on 7th day of weaning to confirm the effects of PTU. Ten pups from each group were euthanized for this experiment. On the day of sacrifice, the pups were weighed and after exposing them to cotton soaked in chloroform for deep anesthesia, blood samples were collected by inserting the needle rapidly under the sternum slightly to the left, to reach the heart. Blood was collected into vacutainer via 3cc syringe following cardiac puncture. In the vacutainer, it was allowed to rest for about an hour. Later on, stored in refrigerator until it was centrifuged at 3000 revolutions per minute for 20 minutes. The tubes were labelled meticulously and were put into freezer set at -80°C. Rat specific enzyme linked immunosorbent assay kit was used for the estimation of total serum T3, T4 and TSH levels.

To remove the brain of 22 days old pups, the scalp was retracted and an incision was made in the skull along the midline. The brain was clearly visible with naked eye examination. It was then extracted from the skull with the help of a spatula and weighed immediately. The meninges were finely cut with scissors and after carefully examining all the parts of the brains under a magnifying lens from both the groups, they were cut across the midline and processed further. As soon as the brains were scooped out and weighed, they were

transferred to 10% formalin for a week, and then serially dehydrated, increasing the concentration of alcohol gradually after each hour during this process. Later, the tissue was cleared in xylene and then embedded in paraffin wax (56 - 58°C melting point) and 3µm thick sections were processed, stained with cresyl violet / Nissl stain<sup>12</sup> and mounted on slides with coverslips for histological examination under a research light microscope. A total of 20-25 slides were prepared from a single brain of a 22 days old pup.

Pyramidal cells characterized by the presence of polygonal shapes with eccentric nucleus and basophilic cytoplasm were counted in the CA3 region of Hippocampus. For this purpose, Leica 1000 DM microscope was used at magnification of 100X after calibrating the ocular grid. A grid was also placed in eyepiece and calibrated in the manner similar to linear micrometer. The Pyramidal cell count was carried out over the ocular graticule on the CA3 area with a calibration factor of 40µm. The neurons inside the squares of the grid were recorded except the cells lying on lower and left edge of the grid. The cells were counted randomly in selected three areas in each section at the magnification of 100X; and the mean was calculated.

## Results:

Data was presented as mean ± SD. As we had 2 independent groups in this study, T-test was performed for comparison of means and as it was a quantitative analysis, both descriptive and inferential statistics were performed, including mean, median, mode, standard deviations, probability, frequencies and percentages;  $p < 0.05$  was considered to be statistically significant on computer software SPSS version 21.

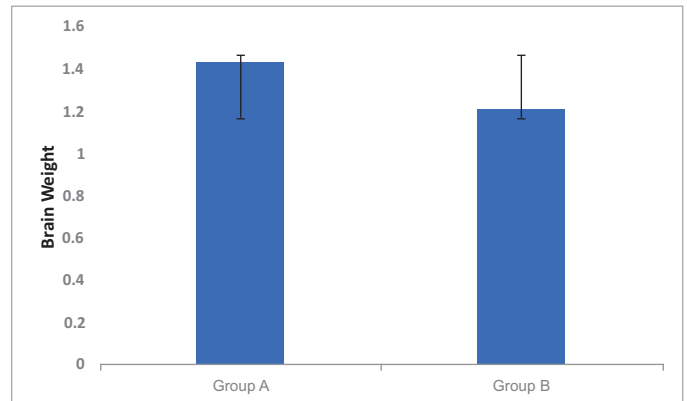
It was observed that there was a significant decrease in the brain weights of group B pups ( $1.21 \pm 0.21$ mg) when compared to the control group A ( $1.42 \pm 0.01$ mg). The thyroxine (T4) level from the experimental group B was significantly decreased to  $27.7 \pm 1.2$  ng/dl compared to  $32.1 \pm 0.9$  ng/dl for the control group, highlighting the effect of PTU. Moreover, the serum levels of TSH were significantly higher in group B ( $21^* \pm 3.7$  ng/dl) as compared to group A ( $15 \pm 2.4$  ng/dl) (Table 1).

**Table 1:** Brain weight and serum TSH, T3, T4 levels in 22 days old pups.

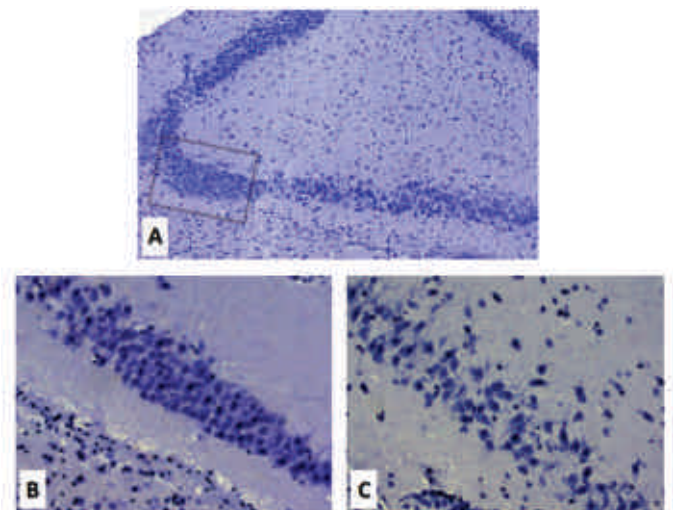
Groups	Brain Weight (mg)	TSH ng/dl	T3 ng/dl	T4 ng/dl
A	$1.42 \pm 0.01$ P = 0.10	$15 \pm 2.4$ P = 0.16	$33.7 \pm 0.5$ P = 0.13	$32.1 \pm 0.9$ P = 0.10
B	$1.21^* \pm 0.21$ P = 0.03	$21^* \pm 3.7$ P = 0.02	$32.3 \pm 0.4$ P = 0.13	$27.7^* \pm 1.2$ P = 0.04

Data is expressed as mean ± S.D (n = 10), where \* indicates P < 0.05

Data is expressed as mean ± S.D (n = 10).



**Figure 1:** Comparison of Brain Weights (mg) Among 22 Days Old Pups.



**Figure 2:** Arrangement of Pyramidal Cells in CA3 Area of Hippocampus

Count of Pyramidal neurons in CA3 region of Hippocampus in 22 days old pups. (40x magnification) in nissl stained slides. The square in A indicates the CA3 area of Hippocampus. Figure B represents the control group (A) where an orderly arrangement of pyramidal cells is observed. C represents PTU treated group (B), where a haphazard arrangement of pyramidal cells is seen.

The pyramidal cell count was done in slides randomly chosen from each group. After 15 readings from each group, a mean count was calculated in both the groups.

**Table 2:** Count of pyramidal cells in CA3 area of hippocampus

Group	Number of Pyramidal Cells (per unit area)
A	44 ± 2.49
B	39* ± 1.24

Data is expressed as mean ± S.D (n = 10), where \* indicates P < 0.5

## Discussion:

Learning and memory are reflected in the intellect of a person and these two functions have an association with the hippocampus. To better understand the effects of hypothyroidism on the arrangement of the pyramidal neurons of hippocampus, this experiment was an attempt to carefully observe the changes in the migration pattern and histological changes, if any, inside the CA3 pyramidal neurons after exposure to maternal hypothyroid state, right from conception to the last day of lactation. Not only the arrangement of pyramidal neurons was observed, but also on the count of these cells was recorded. Maternal hypothyroidism has severe implications on the morphology of the entire developing brain of the fetus, but its effects on learning and memory have a direct association with the serum levels of THs.

The results of this experiment highlight the significant role of thyroid hormones in influencing the anatomy of the hippocampus. Hypothyroidism induces alterations in the number of pyramidal cells of the hippocampal CA3 region. Morphometric examination of sections of Hippocampus from group B revealed fewer pyramidal cells in CA3 area as compared to control (Table 2). Increased oxidative stress might have led to amplified degeneration and apoptosis resulting in decreased count of Pyramidal cells.

There is scarcity of literature on the effects of maternal hypothyroidism on the morphology and arrangement of Pyramidal cells of hippocampus. A study conducted by Cooke et al. in 2014<sup>13</sup> on humans showed that the hypothyroid adults had lesser volume of hippocampus as compared to normal. Similarly, in this study, there was also a significant reduction seen in the weights of brains of group B pups (Table 1). This decrease in weight of the brain suggests that maternal exposure to impaired levels of THs, regardless of whether it is for a brief or longer period of time, can affect the architecture

of brain in neonates. On the contrary, Schwartz et al., in 1997<sup>14</sup> did not report any significant decrease in the brain weight of 21 days old fetus taken out from hypothyroid pregnant rats. This indicates that the first 3 weeks after birth in rats are critical and the brain is vulnerable to damage if not exposed to adequate levels of thyroid hormones. Thyroid hormones perhaps exert their influence in the first 3 weeks of life in pups, and if the new born pups are devoid of thyroid hormones, the architecture of the neurons is impaired and as a result, apoptosis sets in. This is what might have happened in this experiment, evident by the decrease in the number of neurons and overall reduction in brain weight.

It has been observed through various experiments that hypothyroidism, even for a brief period, affects transmission of synapsis inside the hippocampus.<sup>15</sup> Maternal hypothyroidism during lactation leads to incomplete development of the brain in the offspring,<sup>16</sup> indicating that in the present study, lack of thyroid hormones influenced not only the brain weight and provoked apoptosis, but also impaired the migration of pyramidal cells in CA3 area. The arrangement of pyramidal neurons was well preserved in group A (Figure 2B), whereas group B not only showed haphazard arrangement, but also a decrease in the count of these cells (Figure 2C).

The precise action of THs in its regulation of mechanisms during the process of brain development during intrauterine period is less understood. Specific nuclear receptors of THs have been demonstrated in brains of fetal rats by Barez Lopaz et al (2017)<sup>17</sup>, which is an indication of the significant role of thyroid hormones in the developing brain. Gutiérrez-Vega et al. (2020)<sup>18</sup> also demonstrated the presence of increasing type II 5'-iodothyronine deiodinase activity in the fetal brain, an enzyme responsible for the conversion of T4 into T3. These findings led to the conclusion that THs are necessary for normal brain development both during the fetal and early postnatal period.

A transient deficiency or increase of maternal THs during pregnancy can have deleterious consequences on brain morphology in the offspring, as highlighted through this study. During intrauterine life, the significant actions of THs inside the fetal brain occur at the time when TH levels are comparatively lower in the serum compared to those in the mother and the HPT axis is not fully functional.<sup>19</sup> The exact mechanism by which THs induce its effects in the developing brain is not well understood, but it is generally stated after evaluating the results of previous studies that hypothyroidism causes significant

morphological irregularities in the developing brain as a whole, and its effect on the morphology of the pyramidal neurons in the hippocampus is remarkable.<sup>20</sup>

### Conclusion:

Thyroid Hormones regulate the development of rat brain throughout pregnancy and lactation and maternal hypothyroidism not only exerts its influence on the arrangement of Pyramidal neurons of CA3 area of hippocampus, but it also decreases their count. Overall, it also effects the weight of the brains and significantly raises the levels of TSH in the neonatal pups. However, further experimentation is needed in this regard.

**Limitations of this study:** A detailed histological study under an electron microscope would have further added to the quality of research by providing minute details of the pyramidal neurons, which would have given a better understanding of sequential anatomical changes in the hippocampus of hypothyroid pups.

**Ethical Approval:** Given

**Conflict of Interest:** The authors declare no conflict of interest.

**Funding Source:** None

### References:

- Hippocampus [Internet]. Encyclopædia Britannica. Encyclopædia Britannica, inc.; [cited 2022Oct3]. Available from: <https://www.britannica.com/science/hippocampus>
- Lepage C, Muehlmann M, Tripodis Y, Hufschmidt J, Stamm J, Green K. Limbic system structure volumes and associated neurocognitive functioning in former NFL players. *Brain Imaging and Behavior*. 2019; 13(3): 725-734.
- Bernal J. Thyroid hormones and brain development. *Hormones, Brain and Behavior*. 2017;:159–84.
- Hidayat M, Mahar Y, Lone KP. Neuronal damage in brains of first- and second-generation pups born to hypothyroid Wistar rats. *Khyber Med Univ J*. 2020; 12(3): 197-203. doi: 10.35845/kmuj.2020.20183.
- Talhada D, Santos CRA, Gonçalves I, Ruscher K. Thyroid Hormones in the Brain and Their Impact in Recovery Mechanisms After Stroke. *Front Neurol*. 2019; 10:1103. doi:10.3389/fneur.2019.01103
- Becker EB and Bonni A. Cell cycle regulation of neuronal apoptosis in development and disease. *Progress in neurobiology*. 2004; 72(1): 1-25.
- Cherubini E, Miles R. The CA3 region of the hippocampus: how is it? What is it for? How does it do it?. *Frontiers in cellular neuroscience*. 2015 ;9:19.
- Maruszak A, Thuret S. Why looking at the whole hippocampus is not enough—a critical role for anteroposterior axis, subfield and activation analyses to enhance predictive value of hippocampal changes for Alzheimer's disease diagnosis. *Frontiers in cellular neuroscience*. 2014 ;8:95.
- Hamdy N, Eide S, Sun HS, Feng ZP. Animal models for neonatal brain injury induced by hypoxic ischemic conditions in rodents. *Exp Neurol*. 2020 Dec;334: 113457. doi: 10.1016/j.expneurol.2020.113457.
- Anderson GW, Schoonover CM and Jones SA. Control of thyroid hormone action in the developing rat brain. *Thyroid*. 2003;13(11): 1039-1056.
- AVMA guidelines for the euthanasia of animals: 2013 edition - indiana [Internet]. [cited 2022Oct18]. Available from: [https://www.in.gov/boah/files/AVMA\\_Euthanasia\\_Guidelines.pdf](https://www.in.gov/boah/files/AVMA_Euthanasia_Guidelines.pdf)
- Bancroft, J.D. and Cook, H.C. (1984) manual of histological techniques. New York Churchill Livingstone. -references - scientific research publishing. [cited 2022 Oct18]. Available from: [https://www.scirp.org/\(S\(1z5mqp453edsnp55rrgict55\)\)/reference/ReferencesPapers.aspx?ReferenceID=230710](https://www.scirp.org/(S(1z5mqp453edsnp55rrgict55))/reference/ReferencesPapers.aspx?ReferenceID=230710)
- Cooke GE, Mullally S, Correia N, O'Mara SM, Gibney J. Hippocampal volume is decreased in adults with hypothyroidism. *Thyroid*. 2014 ;24(3):433-40.
- Schwartz HL, Ross ME and Oppenheimer JH. Lack of effect of thyroid hormone on late fetal rat brain development. *Endocrinology* .1997;138(8): 3119-3124.
- Dong J, Yin H, Liu W, Wang P, Jiang Y and Chen J. Congenital iodine deficiency and hypothyroidism impair LTP and decrease C-fos and C-jun expression in rat hippocampus. *Neurotoxicology*. 2005;26(3): 417-426.
- De Escobar GM, Obregón MJ and Del Rey FE. Role of thyroid hormone during early brain development. *Eur J Endocrinol* .2004;151(Suppl\_3): U25-U37.
- Bárez-López S, Guadaño-Ferraz A. Thyroid Hormone Availability and Action during Brain Development in Rodents. *Front Cell Neurosci*. 2017;11:240. doi: 10.3389/fncel.2017.00240
- Gutiérrez-Vega S, Armella A, Mennickent D, Loyola M, Covarrubias A, et al. High levels of maternal total triiodothyronine, and low levels of fetal free L-thyroxine and total tri-iodothyronine are associated with altered deiodinase expression and activity in placenta with gestational diabetes mellitus. *PLOS ONE* 2020;15(11):

- e0242743.<https://doi.org/10.1371/journal.pone.0242743>
19. Köhrle J. Thyroid hormone transporters in health and disease: advances in thyroid hormone deiodination. *Best practice & research Clinical endocrinology & metabolism* 2007;21(2):173-191.
  20. Moog NK, Entringer S, Heim C, Wadhwa PD, Kathmann N, Buss C. Influence of maternal thyroid hormones during gestation on fetal brain development. *Neuroscience* 2017;342:68-100. doi: 10.1016/j.neuroscience.2015.09.070.